

Musculoskeletal hydatid cyst: a case series

Musculoskeletal hydatid cyst

¹Saniye Goknil Calik, ²Mustafa Calik¹Department of Emergency and First Aid Program, KTO Karatay University Vocational School of Health²Department of Thoracic Surgery, Health Sciences University, Konya Training and Research Hospital, Konya, Turkey**Abstract**

Musculoskeletal hydatid cyst (HC) is sporadic and occurs in less than 2% of all locations. We found only three cases of HC between January 2008 and December 2018. Many social causes which indicate ethnicity, age, education, occupation, and nationality support the life cycle and the prevalence of HC in many parts of the world. Although an infectious disease spread all over the world except Antarctica, it is considered a neglected tropical disease. HC has changed and spread across the globe due to the migration and traveling, particularly from endemic regions, growing elderly population, and immunosuppression. The global or broader perspective and local solutions for HC are necessary. We seem to be losing the battle with HC. Clinicians must be aware of the importance of echinococcosis in public health, even in non-endemic areas. Now we must understand that we cannot cope with it as an individual or as a single society or country.

Keywords

Neglected Disease; Musculoskeletal; Hydatid Cyst

DOI: 10.4328/ACAM.20020 Received: 2019-11-05 Accepted: 2019-11-25 Published Online: 2019-11-27 Printed: 2020-07-01 Ann Clin Anal Med 2020;11(4):349-353

Corresponding Author: Mustafa Calik, Department of Thoracic Surgery, Health Sciences University, Konya Training, and Research Hospital, Konya, Turkey

E-mail: drmcalik@hotmail.com GSM: +90 505 858 48 98

Corresponding Author ORCID ID: <https://orcid.org/0000-0001-9963-5724>

Introduction

Hydatid Cyst (HC) is a chronic, complex, and neglected tropical infection caused by *Echinococcus* (*E.*) *granulosus*, *E. alveolaris*, *E. multilocularis*, and *E. vogeli*, a cestode spread all over the world except Antarctica affecting an approximately 3 million people, especially in rural communities due to inadequate environmental health, preventive medicine, and veterinary services [1]. The most common cause of HC in humans is *E. granulosus* that is found in domestic animals, whereas rarely *E. multilocularis* that is observed in wild animals. *Echinococcus vogeli* and *Echinococcus oligarthrus* are underlying reasons for polycystic diseases and rarely cause an infection in humans. Although it belongs to prehistory, even today, we continue to make discoveries about HC. Newer, *Echinococcus shiquicus*, and *Echinococcus felidis* species have been added in small mammals in Tibetan plateau and lions in Africa, respectively. Their zoonotic potentials and spreading have been investigated. The most frequent localizations are liver and lungs though HC could be primary or secondary anywhere of the body. Musculoskeletal hydatid cysts (MSHC) are rare affecting less than 2% of all HC patients even in endemic regions [2-4]. Diagnosis and treatment are quite challenging. Herein, we aim to describe patients with MSHC that is little chance of seeing outside endemic areas by many physicians.

Case Report

In this study, the data of the patients who underwent surgery for hydatid cyst in our clinic between January 2008 and December 2018 were retrospectively analyzed. We found only three cases in the last decade. All procedures performed in studies involving human participants were in accordance with the ethical standards of the institutional and/or national research committee and with the 1964 Helsinki Declaration and its later amendments or comparable ethical standards. Patients included in this study were accepted from the hydatid cyst database collected for another review. Written informed consent was not obtained from patients due to the retrospective nature of this study.

Case 1: A 41-year-old male patient presented with left back pain to our clinic. No anomaly was found in the physical examination and laboratory tests. In his medical history, there was an operation for left lung hydatid cyst 20 years ago. In thorax CT examination, a mass showing 75 x 40 x 70 mm cystic enlargement in vertebra transverse process (Figure 1A and B) and left 9th and 10th Costa and destruction (Figure 1 C and D) were observed. After all diagnostic test was completed, he underwent surgery. A left-sided posterolateral thoracotomy was performed. Left hemithorax was explored through an incision. After that accessing the thorax, the cohesion has been separated by obtuse and sharp dissections. A smooth marginated 75 x 40 x 70 mm lobulated lesion has been specified, adjacent to T10 vertebra. The mass was protruding into the hemithorax and the adjacent soft tissue. A mass showing cystic enlargement in vertebra transverse process and 9th and 10th costa and destruction were observed. It was also noted that it was a degenerated hydatid cyst when it was separated from the surrounding structures. Multiple germinative membranes have been removed. The related area was resected with a surgical

border of two cm as enblock. Vertebra corpus and spinal cord were intact. No additional surgery for the vertebral corpus was performed. The chest wall was closed primarily without any grafting.

Case 2: A 64-year-old man was admitted to our hospital with a six-month history of a painless slow-growing mass in his left hemithorax. He had no other complaints. His medical history and physical examination revealed no pathologies except for mass on the left latissimus dorsi muscle. Upon physical examination, there was a 6 × 4.5-cm, non-tender, mobile, and smoothly outlined mass on the left latissimus dorsi muscle. There were no signs of skin inflammation such as induration, heat, or redness. The mass was palpated subcutaneously over the left latissimus dorsi muscle (Figure 2A, B). All routine laboratory tests were standard. Thorax computed tomography (CT) showed two cystic pulmonary nodules, 4.3 × 3.2 and 1.5 × 2 cm in diameter (Figure 2C), in the right inferior lobe. Magnetic resonance imaging (MRI) demonstrated a well-circumscribed multilocular cyst (most enormous size, 6 × 4.5 cm) in the left latissimus dorsi muscle (Figure 2D).

Further radiological assessments revealed no other organ involvement. The patient underwent a two-step surgery. The first step was excision of the cyst with the surrounding muscle tissue in his left hemithorax. The next step involved cystectomy plus capitonnage performed on the lung lesions through the right posterolateral thoracotomy.

Case 3: A 64-year-old female patient was admitted to our hospital with complaints of back pain, weakness, and numbness in hands and feet about three years ago. No particular circumstances have been specified in a physical examination and lab tests at the admission. However, in the thorax BT, in the left lung upper lobe apicoposterior, a smooth contoured 45x35mm mass lesion penetrating spinal canal, destroying thoracal 4th (T4) vertebra corpus lateral was detected (Figure 3A). Interpreting a neurogenic tumor, it had been suggested a histopathologic correlation and operation; on the other hand, the patient had refused any treatment or surgery. Upon increasing complaints for three years, the patient then has admitted to an emergency room in our hospital. It has been reported that she was hardly walking and using her hands. At the admission, she was generally healthy, conscious, cooperative and oriented. Physical examination revealed only minimal bilateral lower extremity weakness. All lab test results were typical, and HC IHA was positive. In the thorax BT, in the left lung upper lobe apicoposterior, a smooth contoured 45x35mm mass lesion is specified, penetrating spinal canal, destroying thoracal 4th (T4) vertebra corpus lateral (Figure 3B). In thoracic MR screening, a smooth marginated and macro lobulated contoured 40x37x35 mm mass lesion has been specified, explicitly restricting the neural foramen at T4, extending to arcus aorta and neighboring to left lung at lateral, hypointense on T1 and hyperintense on T2A, and having involvement of minimal homogenous contrast after IV Gd injection. The specified lesion has been observed as extending into the neural foramen and causing destruction in the vertebral corpus and posterior elements (Figure 3C). A posterolateral thoracotomy has been realized through 4th intercostal space; after accessing to the thorax, the cohesion has been separated by obtuse and sharp dissections. Thorax

was explored, and a smooth marginated 4x3.5x3.5cm lobulated lesion has been specified, neighboring at T4 lateral to arcus aorta and left lung. The lesion extending into the spinal canal has been separated from surrounding tissues, and multiple germinative membranes have been removed. Medulla spinalis was intact. No additional surgery has been made since the location was in the corpus. Thorax tissues have been closed in due form.

All patients were first admitted to the emergency (ER) due to their complaints. All procedures were performed in one step except for the second patient who underwent two-step treatment under general anesthesia in the operating room. Following pre-operation preparations, surgeries were carried out with the patient in the lateral decubitus position. No perioperative complications were encountered. All diagnoses were confirmed by surgical and histopathological evaluation. Respectively, the first patient was discharged on the sixth day, the second and the third patients on a ninth day postoperatively. The patients were treated with albendazole (10 mg/kg/ day) for a 20-day single cycle per month. The treatment lasted for three months in the first two patients and six months in the third. There was no recurrence and complications at 24-month follow-up.

Discussion

Although it belongs to prehistory, understanding of the lifecycle of cyst has been realized in the last two centuries. Today, there are almost no countries with any HC due to travel and migration from endemic regions. Eggs can stay alive for months on the grasslands, gardens, fomites, sands, or waters and can be eaten with dirty foods such as vegetables, fruits, or herbs or drunk in murky water. By swallowing the cystic form of the parasite, a human accidentally becomes the host, who is not in the normal life cycle. The human immune system cannot destroy cysts. The cysts in the duodenum via vena porta may spread anywhere in the body haematogenously or lymphogenously [2-5]. Liver and lungs, as the most frequent locations, behave as a natural filter for HC, thus 90% of the cases have developed in these organs. The rest 10% localizes in the organs having soft tissues, so-called "rare locations" such as spleen, pancreas, gall bladder, adrenal gland, pelvis, seminal vesicle, heart, bone, breast, kidney, thyroid gland, and muscles. Although many hypotheses are recommended for rare localizations, their pathogenesis is not fully understood. One of them, the shunt-escape theory is the most accepted one as we have also agreed [2].

The diagnosis may be achieved through a holistic evaluation of clinical, radiological, and lab data along with anamnesis. The signs and symptoms of MSHC vary depending on the location of the site, adjacent tissues, and complications. The first and most common symptom was a slowly growing painless mass and the second was back pain in all our patients. These symptoms are consistent with the literature. Radiological screening methods are the first and the most important alternative for the diagnosis. Lab tests have a limited effect. Bone involvement compared with other settlements is entirely different. Only 0,5-2% of the HC cases involved bones, whereas half of them involved vertebrae. The location and growth of HCs in the muscle are similar to other areas. Costal and vertebral

localization of HCs are extremely rare and differentiated from other bone ones with destruction in rib or bone matrix and rupture risk for surrounding tissues and recurrence. First of all, it is localized in calcium-containing bone although it is porous, unlike soft tissue. Dew has demonstrated it; embryos have been restricted to bone due to high vascularity and have been found to invade other bone and peripheral tissue fragments.

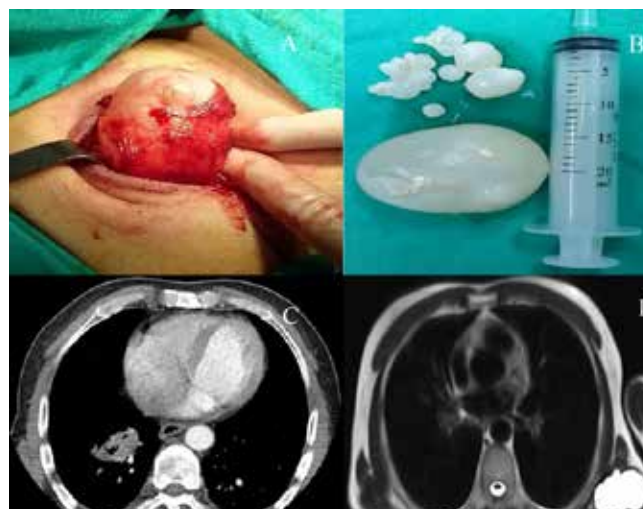

Figure 1. A three-dimensional computed tomography scan showing an expanding cystic mass in the 9th and 10th ribs with destruction of the vertebral transverse process, seen in the (A) anterior and (B) anterior view with soft tissue; and conventional thorax CT of the Axial (C) and coronal (D) images show destruction in the ninth and tenth ribs.

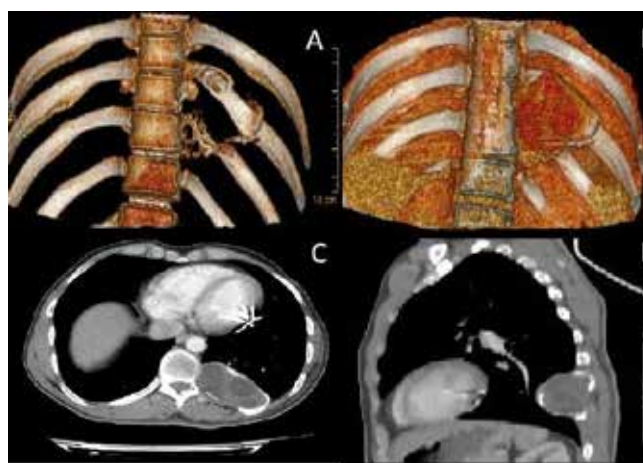


Figure 2. (A) Mass in the left latissimus dorsi muscle and (B) the cysts were resected intact with surrounding tissues. (C) Thorax CT showed two cystic pulmonary nodules, 4.3 x 3.2 and 1.5 x 2 cm in diameter in the right inferior lobe. (D) MRI demonstrated a well-circumscribed multilocular cyst (most enormous size, 6 x 4.5 cm) in the left latissimus dorsi muscle.

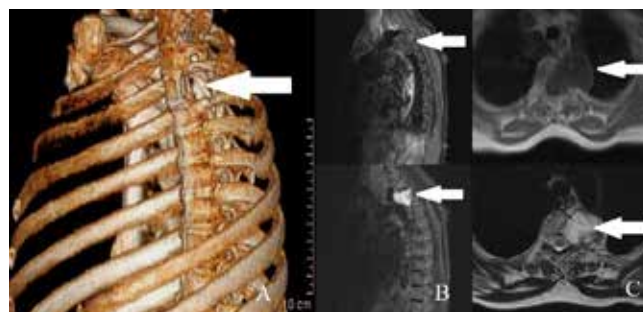


Figure 3. (A) The three-dimensional CT scan showing a cystic and expanding mass (white arrows) is seen at T4 level with the destruction of the vertebral body, (B) Coronal, and (C) axial MRI scan of thoracic T4 vertebral level (white arrows).

These grow from 1 to 5 mm a year [5]. As in our cases, rare localizations are confused with tumors, abscesses, and other cysts and lead to diagnostic problems. Preoperative diagnosis was as follows: Case 1 was a thoracic wall tumor, case 2 a lipoma, and finally, case 3, a neurogenic cyst.

Many social causes that indicate ethnicity, age, education, occupation and nationality support the life cycle and the prevalence of HC in many parts of the world called endemic regions. Although the different communities in those areas were far from each other, they had different cultural practices, such as keeping many dogs, keeping much livestock, and preserving street dogs in China that caused the same result that acted as social determinants of the disease. HC still is a significant health problem, particularly in its regions. Almost all sectors are consisting of undeveloped or developing low socio-economic level countries. In these countries or areas, most of the population lives in rural areas or very crowded urban areas with unhealthy facilities. The inhabitants of these areas are at high risk because of the close contact with animals and non-compliance with hygiene and health principles. They are always connected to animals as food, transport, labor and security resources. It seems to be continuing for reasons that include an appropriate climate and ecological conditions, nomadism, poor hygienic conditions, and low education, local customs and beliefs, joint feeding grounds, uncontrolled slaughtering under adverse conditions even on open ground, carnivorous animals particularly wild or owned dogs accessing the remnants of the free slaughtered animals even in the far future.

HC, in theory, is a controllable even eradicable disease. It has been under control in small island countries like Iceland, New Zealand, Tasmania, Cyprus and Falkland Islands, as well as in limited areas in Argentina and Chile [6]. Despite these encouraging small achievements, millions of people still need treatment for neglected diseases that seem to be challenging to treat, like HC. We seem to be losing the battle with HC. The success of the control program in islands and limited areas is known. The control studies carried out by nation-states and limited international organizations in larger geographies have not been successful. For example, the role of dogs and pets in the transmission of HC is particularly crucial in western China, Central Asia, and the Middle East. It may be more important in Europe than previously expected. However, especially the wildlife in Africa is added to the cycle. The global or broader perspective and local solutions for HC are necessary. A well-funded government and/or international institution-focused control program should be implemented for greater local control and success.

For this, preventive chemotherapy, intensified disease management, vector, and intermediate host control, veterinary public health at the human-animal interface, and provision of safe water, sanitation, and hygiene should be provided through a unified, multidisciplinary, institutionalized and international effort. The focus should be on the areas that are most at risk and mostly on animal communities involved in the transfer, and progress should be monitored effectively through robust epidemiological surveillance systems. Also, since most of these HC diseases are caused by poverty, it will provide continuous success with long-term economic growth and permanent

measures such as better sanitation, safer water, and food supply and especially in education. World Health Organization (WHO) aims to prevent contagion to human beings by 2050. Pharmaceutical industry donated 600 million doses of albendazole and mebendazole, the drugs used in the treatment of HC, to the WHO. Despite numerous obstacles and difficulties, this goal is very ambitious but can be achieved [1, 7].

HC is endemic in Turkey and the notification is compulsory, the real number of the disease is much more than it is officially stated. In the endemic regions of the country we live in, there is little change in the socioeconomic level in the last century. The same conditions for infection still continue to take place. It is interesting to note that although MSHC is less than 2% of total HC cases in endemic areas and chronic disease, patients first apply to the emergency department. It also needs to be investigated and discussed. It can be easily misdiagnosed in busy and crowded ERs such as Turkey.

Even today, MSHC's treatment is based on the surgeon's belief or experience and medium-low quality evidence. "Best treatment" is still the topic of discussion and quite tricky due to recurrence in the MS. As for cancer patients, recurrence and long-term follow-up should be implemented for MSHC. For this reason, we continue to follow up with each patient in a period of 6 months. However, further studies with long-term follow-up are still needed to base the echinococcal therapeutic strategy on evidence.

Although an infectious disease spread all over the world except Antarctica, is considered a neglected tropical disease. HC is the twelfth of seventeen neglected tropical diseases announced by the WHO. HC causes severe adverse effects on national revenues due to its increasing health costs as well as losses in the livestock industry. It is responsible for approximately 3 million people worldwide and is responsible for spending more than \$ 3 billion each year. The prevalence of the disease in developing countries is ten thousand times higher than in developed countries [1]. HC has changed and spread all over the world in recent years due to migration and traveling particularly from endemic regions, growing elderly population, and immunosuppression. Therefore, clinicians must be aware of the importance of echinococcosis in public health, even in non-endemic areas. Now we must understand that we cannot cope with it as an individual or as a single society or country. We should fight against this disease together or we lose altogether. Even the developed and prosperous European countries in our west encounter HC because of their population movements. A multidisciplinary approach is a prerequisite for diagnosis and treatment strategy.

Scientific Responsibility Statement

The authors declare that they are responsible for the article's scientific content including study design, data collection, analysis and interpretation, writing, some of the main line, or all of the preparation and scientific review of the contents and approval of the final version of the article.

Animal and human rights statement

All procedures performed in this study were in accordance with the ethical standards of the institutional and/or national research committee and with the 1964 Helsinki declaration and its later amendments or comparable ethical standards. No animal or human studies were carried out by the authors for this article.

Conflict of interest

None of the authors received any type of financial support that could be considered potential conflict of interest regarding the manuscript or its submission.

References

1. Khan A, Naz K, Ahmed H, Simsek S, Afzal MS, Haider W, et al. Knowledge, attitudes and practices related to cystic echinococcosis endemicity in Pakistan. *Infect Dis Poverty*. 2018; 22;7(1):4. DOI: 10.1186/s40249-017-0383-2.
2. Calik M, Calik S. G, Esme H. Vertebral Hydatid Disease: White Cancer. *Respir Case Rep*. 2017;6(2):103-6 DOI: 10.5505/respircase.2017.38981
3. Calik S.G, Calik M, Yesildag M, Esme H. Intramuscular Hydatid Cyst Report of an Unusual Case. *JEMCR*. 2016; 7(4): 61. DOI: 10.5152/jemcr.2016.1569
4. Duran F M, Calik M, Calik S.G, Duzgun N, Esme H. Costal Hydatid Cyst: A Rare Case Report. *Respir Case Rep*. 2018;7(2):71-4. DOI: 10.5505/respircase.2018.26213
5. Kaloostian P.E, Gokaslan Z.L. Spinal Hydatid Disease: A Multidisciplinary Pathology. *World Neurosurg*. 2015;83(1):52-3.
6. Escolà-Vergé L, Salvador F, Sánchez-Montalvá A, Escudero-Fernández JM, Sulleiro E, Rando A, et al. Retrospective Study of Cystic Echinococcosis in a Recent Cohort of a Referral Center for Liver Surgery. *J Gastrointest Surg*. 2019; 23(6). 1148-56. DOI: 10.1007/s11605-018-3971-y.
7. Wen H, Vuitton L, Tuxun T, Li J, Vuitton DA, Zhang W, et al. Echinococcosis: advances in the 21st century. *Clin Microbiol Rev*. 2019; 32(2). DOI: 10.1128/CMR.00075-18

How to cite this article:

Saniye Goknil Calik, Mustafa Calik. Musculoskeletal hydatid cyst: a case series. *Ann Clin Anal Med* 2020;11(4):349-353